



THE SCOPE

MEDICAL EDITION



ISSUE 01 | SECOND QUARTER 2020

Transitioning
Medical Practices
Post-COVID-19

MLMIC Releases
*Million Dollar Claims -
A Closer Look*

Million Dollar Claims:
Diagnostic Errors
Explored

Case Study:
The Disastrous Effects
of "Anchoring"

INSIDE

- 2 Transitioning Medical Practices Post-COVID-19: Key Underwriting Considerations to Ensure Proper Coverage
- 4 MLMIC Releases *Million Dollar Claims - A Closer Look*
- 6 Million Dollar Claims: Diagnostic Errors Explored
- 11 Case Study: Cognitive Bias in Medical Diagnoses - The Disastrous Effects of "Anchoring"
- 16 MLMIC Stands with You During the COVID-19 Pandemic

Editorial Staff

John W. Lombardo, MD, FACS - Publisher

John Scott - Editor

William Fellner

Thomas Gray, Esq.

Kathleen Harth

Anne Heintz

Pastor Jorge

Edward Krause

Matthew Lamb, Esq.

Mirsade Markovic, Esq.

Danielle Mikalajunas Fogel, Esq.

Patricia Mozzillo

Robert Pedrazzi

Mary Roulette

Daniela Stallone



MLMIC's risk management online program is very informative. Each course provides insight into managing risk, which actually helps physicians become better doctors. ”

Peter A. Knight, MD
Thoracic Surgeon

MLMIC Insurance Company
Policyholder | Rochester, NY



EXECUTIVE MESSAGE

To Our MLMIC Insurance Company Policyholders:

When work began on the development of a new publication for MLMIC Insurance Company policyholders, the world was a different place. Our kick-off meeting was held in a small room in MLMIC's Manhattan offices with a dozen or so of us around a table, elbow-to-elbow. How times have changed! COVID-19 and the resulting crisis have been the agents of this change.

What has taken place in New York in just a few months is breathtakingly stunning. New Yorkers and all Americans, along with billions more around the world, experienced a situation both unforeseen and, for most of us, unimaginable.


As the world changed, work on this publication continued, albeit in a different manner. Zoom chats and group emails replaced roundtable planning sessions.

As the country as a whole, and New York especially, continues to reopen, I'm pleased to present to you *The Scope*, MLMIC Insurance Company's new newsletter for physicians, medical facilities and practices, and advanced practice provider policyholders.

The Scope will present topics and information designed to help our policyholders avoid medical professional liability litigation and, through this, improve patient care. Each issue will feature illustrative, real-world depictions of litigation that took place against fellow professionals here in New York State. Healthcare attorneys from Fager Amsler Keller & Schoppmann, LLP, counsel to MLMIC, and MLMIC Risk Management professionals will provide actionable direction designed to protect you, your practice, and your patients. *The Scope* will also be a vehicle for the latest MLMIC Insurance Company information on everything from policy updates to the announcement of new, value-added policyholder benefits.

We recognize that it is you, our policyholders, who are out there in the field caring for patients throughout NYS. You know best what is happening in the practice of medicine, and we'd like to hear from you. What lessons have you learned from your experiences during the COVID-19 outbreak? Have you made changes to your practice or its operation that you plan to keep in place post-COVID-19? What topics would you like addressed in a future issue of *The Scope* that will most directly help you?

We very much value your feedback and ask that you please not hesitate to reach out to us at any time at (212) 576-9600 or jscott@mlmic.com.



John W. Lombardo, MD, FACS
Chief Medical Officer, MLMIC Insurance Company

Underwriting Update

COVID-19 is an evolving/developing situation that may warrant additional guidance from MLMIC, the State of New York and/or the Department of Financial Services. Therefore, policyholders should consult MLMIC's website and its related COVID-19 resources frequently for updated information [MLMIC.com/covid-19](https://www.mlmic.com/covid-19).

Transitioning Medical Practices Post-COVID-19:

Key Underwriting Considerations to Ensure Proper Coverage

MLMIC Insurance Company remains committed to assisting its policyholders throughout the COVID-19 crisis. In accordance with direction from New York State governance, MLMIC has undertaken several actions, and continues to develop new measures to support its policyholders as they transition back into practice and resume suspended services.

The following important update will provide guidance for those MLMIC policyholders who may have adjusted their coverage in response to changes to their practices made during this time.

Returning from a "Suspension of Practice"

For those policyholders who had requested and received a "suspension of practice" (*Temporary Leave of Absence*

Endorsement) change endorsement to their policy due to temporarily discontinuing to provide professional services, it is important to be aware that MLMIC was obligated to notify their certificate of insurance (COI) holders of this suspension. The notice would have clearly stated that **no coverage is afforded for Professional Services rendered during the suspension period.**

Therefore, it is essential that policyholders who had their policies endorsed as such **notify MLMIC in writing prior to their return to practice (click here and select Policy Inquiry dropdown item)**, with a request to have a *Temporary Leave of Absence Reinstatement Endorsement* issued to their policy, specifying the desired effective date for such reinstatement of their coverage. Reinstatement notices will be sent

to all active COI holders upon issuance of this Reinstatement Endorsement.


Returning to Full-Time Practice from Part-Time

Prior to returning to full-time practice, policyholders who had their policies endorsed to part-time (20 or less hours per week) practice are required to notify MLMIC in writing (**click here and select Policy Inquiry dropdown item**) with their request to have their policy endorsed back to full-time coverage. The desired, prospective effective date of this change must be specified.

A policyholder's failure to notify MLMIC of their return to full-time practice may result in coverage issues for the period in question.

If there are any questions regarding returning from "suspension of

practice” or returning to full-time practice, MLMIC Underwriting is here to assist. Please call us at (800) 275-6564 or [click here](#) to contact MLMIC electronically.



Telehealth/Telemedicine Coverage Dependent on Bordering State Licensure Reciprocity

As physicians and practices return to seeing patients, the expansion of telehealth/telemedicine may well play a new and much larger role. While MLMIC’s Physicians and Surgeons professional liability insurance policy affords coverage for telehealth/telemedicine activities according to the terms and conditions of the policy, there is a key requirement within the definition of “Coverage Territory” that policyholders need to pay particular attention to in order for coverage to exist; specifically, an

insured physician must be “duly licensed” (in both the jurisdiction where the physician is practicing and the jurisdiction where the patient is located while receiving treatment).

Pursuant to New York State’s Executive Order 202.5, New York Law has been temporarily modified to allow physicians licensed anywhere in the U.S. to practice medicine in New York State. This Executive Order also applies to physician assistants, nurse practitioners, registered nurses, and licensed practical nurses from other states.

Other states have enacted similar waivers/orders resulting in a MLMIC policyholder’s ability to render Professional Services using telehealth/telemedicine to patients located in other states that hold licensure reciprocity with New York State. These states currently include New Jersey, Connecticut, Pennsylvania and Massachusetts.

However, since licensure reciprocity is subject to change post-COVID-19 crisis, it is essential that policyholders who participate in telehealth/telemedicine services frequently reference COVID-19 resources ([MLMIC.com/covid-19](https://www.mlmic.com/covid-19)) for updated information on state reciprocity. The treatment of patients in states without such reciprocity could potentially jeopardize a policyholder’s medical professional liability coverage for telehealth/telemedicine services.

**Check out
our blog at
[MLMIC.com](https://www.mlmic.com)**



Read about important developments in medical and dental liability, get risk management tips and sign up for MLMIC Healthcare Weekly.

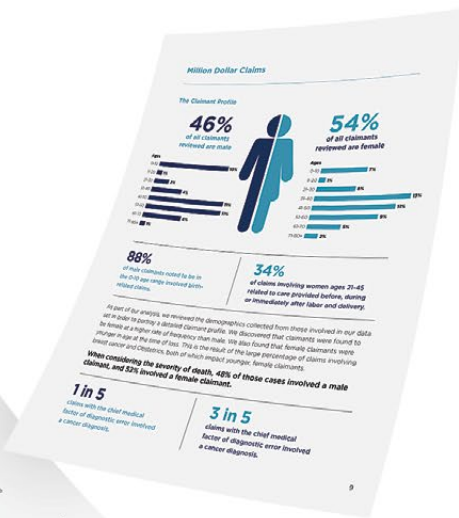
As a value-added service for its policyholders, MLMIC has partnered with the law firm of Fager Amsler Keller & Schoppmann, LLP (FAKS), to follow and advise policyholders on these reciprocity waivers between states and **assist in keeping up-to-date on COVID-19 legal issues during and following the crisis.** MLMIC policyholders may consult with FAKS attorneys on these and other healthcare issues **free of charge** by calling **(855) FAKS-LAW** or [click here](#) to contact FAKS electronically.



MLMIC Releases *Million Dollar Claims - A Closer Look*

As part of MLMIC Insurance Company's ongoing efforts to provide our insureds with information to improve patient safety, MLMIC is pleased to announce that our Risk Management staff have performed an analysis of our closed medical professional liability (MPL) claims occurring over a five-year period that resulted in payment of \$1 million or more: *Million Dollar Claims - A Closer Look*.

This detailed examination will provide valuable insights for our policyholders into the leading causes of loss that contribute to significant payment amounts. This first issue of MLMIC's new publication, *The Scope*, will focus on the topic of diagnostic errors, one of the foremost causes of loss identified in our analysis of million dollar MPL cases.

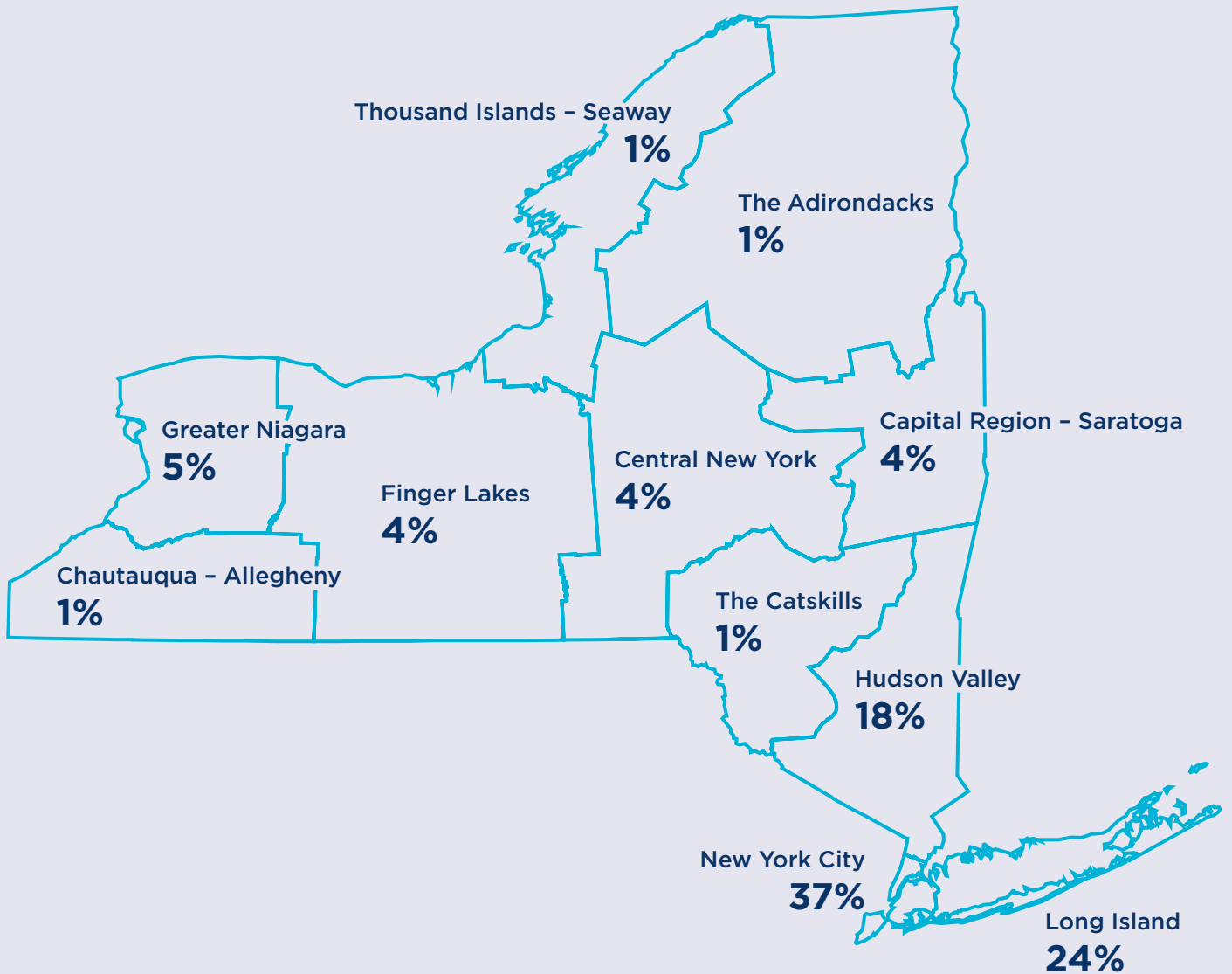


Healthcare practitioners of all specialties and types are encouraged to view MLMIC's complete *Million Dollar Claims* report at MLMIC.com.

Million Dollar Claims

The graphic below illustrates the geographic distribution of claims that resulted in a payout of \$1 million or more.

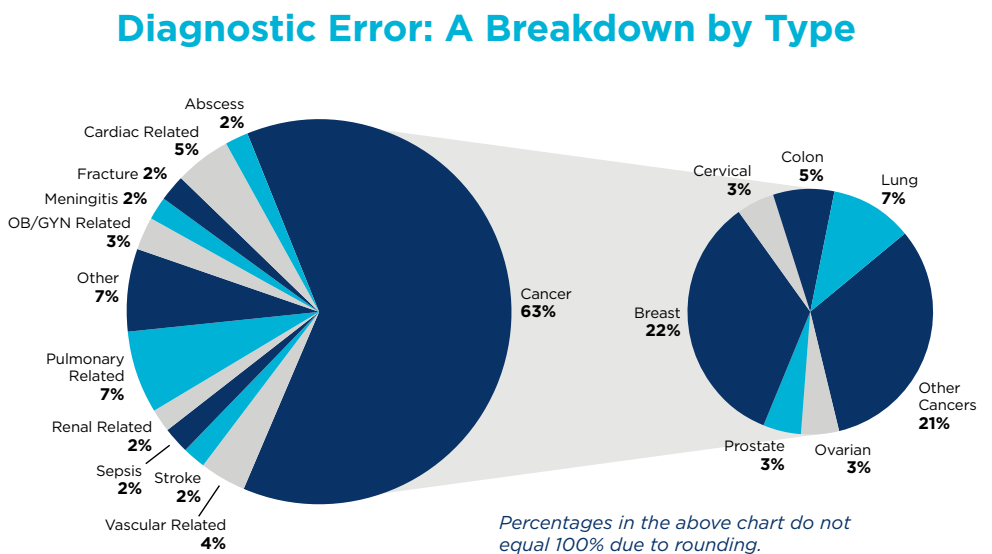
More than 1 in 3 of these claims originated in the southern part of New York State.



Million Dollar Claims: Diagnostic Errors Explored

The detailed examination of closed medical professional liability (MPL) claims presented in MLMIC Insurance Company's *Million Dollar Claims - A Closer Look* found an allegation of error in diagnosis in more than 1 in 3 (35%) of the MPL claims reviewed in our analysis. This result mirrors the findings of others who have studied the root causes of litigation in healthcare. For example, nearly one quarter of closed claims and lawsuits reported to the Medical Professional Liability Association's Data Sharing Project between 2008 and 2017 cited diagnostic error as the primary allegation.¹ Additionally, ECRI's "Top Ten Patient Safety Concerns" for 2020 listed errors in diagnosis as its number one concern.² Diagnostic error has been on ECRI's Top Ten list for several years.

Although often considered underreported, diagnostic error is relatively common, occurring in anywhere from 5% to 20% of emergency department, inpatient and ambulatory visits.



Diagnostic error can occur in any medical specialty. For example, our data reveals cancer diagnoses were missed, delayed or misidentified in 6 out of 10 of the cases where a diagnostic error was identified. These MPL claims were filed against many specialties. Our data also demonstrated that diagnostic error resulted in patient death in 34% of all instances.

Many factors have been identified as contributing to diagnostic

errors, including faulty recognition of symptoms and the failure to act upon a concern raised by another member of the healthcare team.

Communication failures such as inadequate handoffs and the failure to establish clear lines of responsibility among caregivers are also frequently associated with cases of diagnostic error.

"Human" issues such as distractions and excessive workload, interruptions, fatigue

¹ The Medical Professional Liability Association (MPL Association) is the insurance industry trade association that represents a full range of entities doing business in the medical professional liability (malpractice) arena. The MPL Association's Data Sharing Project (DSP) was created to provide critical information needed to pinpoint areas of medical practice that have proven most vulnerable to MPL claims, as well as support efforts seeking effective medical liability reform.

² ECRI is an independent, nonprofit organization improving the safety, quality, and cost-effectiveness of care across all healthcare settings worldwide.

“Human” issues such as distractions and excessive workload, interruptions, fatigue and technology problems can also influence a physician’s ability to diagnose correctly.

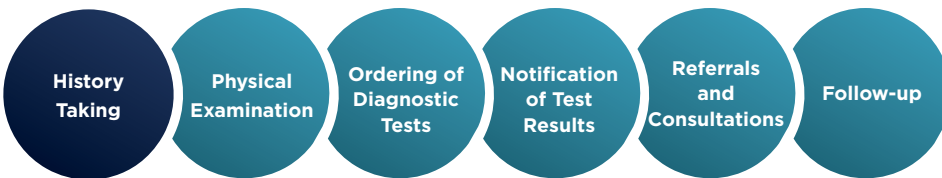
and technology problems can also influence a physician’s ability to diagnose correctly. All of these issues can have a significant impact on patient outcomes, and, unfortunately, often result in malpractice claims against the providers of care.

The extensive study of diagnostic errors has revealed that many errors are the result of process breakdowns during the physician-patient encounter involving individual and system-related factors. Diagnostic errors are

cognitive psychology apply to their analysis. The findings from the study of diagnostic error have demonstrated that how individuals process information influences decision making during the diagnostic process and can contribute to errors. A provisional diagnosis or a plan of care that is predicated on a cognitive bias may negatively impact decision making and adversely affect outcomes.

Providing healthcare professionals with knowledge regarding the influence of cognitive bias in


Diagnostic errors are commonly associated with the following:



commonly associated with history taking, physical examination, ordering of diagnostic tests, interpretation of test results, referrals and consultations, and appropriate follow-up on outstanding studies, test results and consultations.

Researchers have extensively examined the causes of diagnostic error and identified that many principles from the field of

healthcare will enhance their ability to recognize potential pitfalls and reduce the risk of an MPL claim. It has been shown that clinicians frequently use “heuristics” (mental shortcuts or “rules of thumb”) when making a provisional diagnosis, especially when a patient presents with common symptoms. For experienced physicians, heuristics are fast and effective, and generally lead to accurate



Providing healthcare professionals with knowledge regarding the influence of cognitive bias in healthcare will enhance their ability to recognize potential pitfalls and reduce the risk of an MPL claim.

decision making. However, they can have a negative influence on a clinician’s decisions by introducing bias.

(continued on page 8)

Cognitive Influences That Contribute to Diagnostic Errors

BIAS	DEFINITION
Affective	Also called visceral bias; emotional influences can induce thinking errors, including the feelings physicians have about their patients, both positive and negative.
Anchoring	Narrow focus on a single feature in a patient’s presentation to support a diagnostic hypothesis, even if other concurrent features or subsequent information refutes the hypothesis.
Availability	The tendency to think that things that come to mind immediately are more likely or more common.
Blind obedience	Inappropriate deference to the recommendations of authority, either by direct superiors or by expert consultants, even in the absence of a sound rationale.
Confirmation	The tendency to search for evidence to support an initial diagnostic impression, and the tendency not to search for, or even to ignore, evidence that refutes it.
Diagnostic momentum	The tendency of a diagnostic label to become propagated by multiple intermediaries (patients, physicians, nurses, other team members) over time; what might have begun as a possible “working diagnosis” becomes “definite.”
Framing effect	The susceptibility of diagnosticians to be disproportionately influenced by how a problem is described, by whom it is described, or even by the environment where an encounter takes place.
Hindsight bias	Knowing the outcome of an event influences the perception and memory of what actually occurred; in analyzing diagnostic errors, this can compromise learning by creating illusions of the participants’ cognitive abilities, with potential for both underestimation and overestimation of what the participants knew (or could have known).
Overconfidence	The tendency to think one knows more than one does, especially in physicians who might place faith in opinions without gathering the necessary supporting evidence.
Premature closure	Making a diagnosis before it has been fully verified.

One of the most prevalent types of cognitive bias is “anchoring.” This occurs when a physician locks on to one symptom or piece of information in the patient’s initial presentation and discounts subsequent information that may be critical to finding the right diagnosis. “Anchoring” may be seriously compounded by “confirmation bias,” which is the tendency to seek out or interpret data in a way that confirms an initial diagnosis. If a physician has a diagnosis in mind, he/she

One of the most prevalent types of cognitive bias is “anchoring.”

may be more likely to ask questions, test for, and recognize signs and symptoms that support this diagnosis, and dismiss more definitive evidence that might refute it. The case study in this issue of *The Scope* provides a warning on the dangers of anchoring.

Biases in decision making may also result in “premature closure,” which accounts for a large proportion of diagnostic errors. This occurs when the physician fails to consider reasonable alternatives after an initial diagnosis is made.


Strategies to Reduce Diagnostic Error

- Document all clinical decision-making processes using evidence-based practice and justify any deviations from the established standard of care.
- Promptly obtain test results and consults and modify diagnoses and plans of care as indicated.
- Consult with collaborating and/or supervising physicians on all cases of difficult or delayed diagnoses.
- Refer unstable and/or undiagnosed patients with acute symptoms to emergency services.
- Request second opinions and consults as indicated.
- Communicate any changes in diagnoses among all providers of a given patient.
- Enhance clinical skills and reasoning by understanding the sources of cognitive error.
- Recognize any potential diagnostic or cultural biases that may negatively impact care.

Diagnostic error can occur as the result of numerous factors that influence individual healthcare practitioners. Recognizing the risks associated with these factors and deploying strategies to mitigate their potential impact on the processes associated


with healthcare delivery will improve the safety of patient care while lessening the potential for significant exposure to litigation. In future issues of *The Scope*, MLMIC will present other risk management topics that impact healthcare liability and offer strategies to reduce those liability risks.

To review the entire report *Million Dollar Claims – A Closer Look*, please visit our website, MLMIC.com.




Anne Heintz is a Risk Management Consultant for MLMIC Insurance Company.

aheintz@mlmic.com



Joyce McCormack is a Risk Management Consultant for MLMIC Insurance Company.

jmccormack@mlmic.com



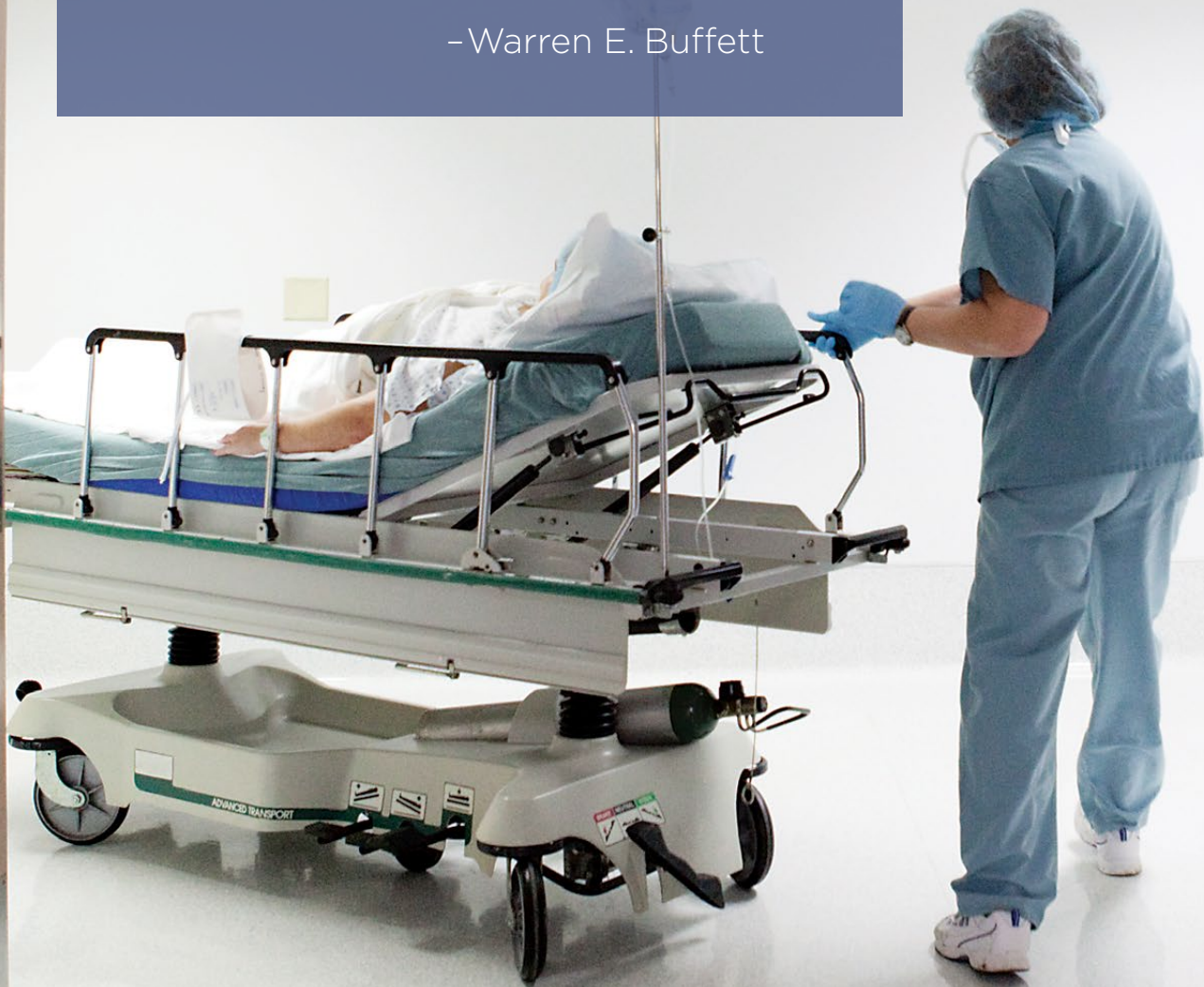Katherine Palella is a Business Data Analyst for MLMIC Insurance Company.

kpalella@mlmic.com

“

It's a good idea
to review past
mistakes before
committing
new ones. ”

- Warren E. Buffett



CASE STUDY:

Cognitive Bias in Medical Diagnoses – The Disastrous Effects of “Anchoring”

This case involves a 42-year-old woman with a markedly significant family history of breast cancer. Her mother and both of her grandmothers had all been previously diagnosed with this disease.

Initial Treatment

In July 2010, the patient presented to the MLMIC-insured general surgeon for a consultation due to an abnormal mammogram performed two weeks prior that showed the onset of a sudden asymmetric density in the upper aspect of the right breast. A mammogram and ultrasound with spot compression views taken that day demonstrated that the density was not persistent, and most likely represented a summation of fibroglandular tissue. A right breast ultrasound showed several solid lesions, and one of those at 12 o'clock, 2 cm from the nipple, was exhibiting acoustical shadowing and was suspicious.

One week later, the patient presented for an ultrasound-guided biopsy of this lesion, which was performed by the general surgeon at a hospital surgery center. The surgeon took two separate cores and a clip

dropped directly under ultrasound guidance, just slightly lateral to the lesion. The pathology was consistent with benign fibrous breast tissue, and the examination revealed no signs of infection, moderate post-op induration, and firmness.

The patient returned for re-examination and a repeat right sonogram in January 2011. The reading was given BI-RADS III for probable benign findings. A breast exam was within normal limits.

In July 2011, a bilateral mammogram revealed a right breast without evidence for malignancy, and a left breast with suspicious microcalcifications with nodularity. Additional sonogram images demonstrated a suspicious mass in the medial upper left breast correlating with abnormal mammogram findings, and an ultrasound guided biopsy was recommended. BI-RADS IV, a suspicious abnormality, was noted.

A bilateral ultrasound revealed no significant interval changes in multiple solid lesions in the right breast.

In August 2011, the patient returned for an ultrasound-guided left breast biopsy at the 10 o'clock position, 4 cm out from the nipple, at the area of the previous scar from which she had fibroadenoma excised in the past. There was a shadowing, hypoechoic nodule in that area, probably related to scarring change or recurrent fibroadenoma. The general surgeon was only able to obtain a single core biopsy due to continued bleeding. She placed a biopsy clip below the hematoma “as best I could but it was hard to see the residual nodule at that point and it certainly is within very close proximity to the nodule.” The pathology revealed benign fibroadenoma.

In March 2012, a left breast ultrasound was performed, and

the history of fibroadenosis was noted. The radiologist pointed out a hypoechoic, irregularly shaped lesion with sharp angles and extensive shadowing at the 10 o'clock position, 8-9 cm from the nipple, had slightly increased in size when compared to the prior study. He recommended an ultrasound-guided biopsy for further evaluation, noted BI-RADS IV, a suspicious abnormality, and called the general surgeon's surgical group to report his findings. The practice's triage notes that same day indicate, "[radiologist] called regarding sono report. He states that in the left breast the solid lesion has gotten larger and still looks like a malignancy, so he recommends a repeat bx." This message was sent to the general surgeon, who asked staff to arrange a follow-up visit for the patient.

In April 2012, the general surgeon saw the patient and noted a history of multiple benign nodules biopsied in each breast, most recently on the left breast at 10 o'clock, which the doctor had biopsied the previous summer and revealed as an atrophic fibroadenoma. She noted a recent follow-up sonogram had revealed it to be slightly larger, and it was given a BI-RADS IV recommendation despite the negative benign biopsy, which was concordant with findings of a fibroadenoma. The surgeon noted that "Its shadowing on sonogram was due to the fact that it was an atrophic fibroadenoma, not because it was a worrisome

"Its shadowing on sonogram was due to the fact that it was an atrophic fibroadenoma, not because it was a worrisome malignancy, pathology proved that, and it had not grown markedly to require surgical excision..."

malignancy, pathology proved that, and it had not grown markedly to require surgical excision. Routine mammogram in July." The patient was scheduled for follow-up in August 2012 with a bilateral mammogram. The general surgeon subsequently left the surgical group and provided no further care to the patient.

Subsequent Follow-up and Diagnosis

The mammogram was performed in early September 2012. The patient was seen at the practice by a nurse practitioner, who reviewed the mammogram findings that indicated "Again seen are calcifications with associated density within the left breast at approximately 9-10 o'clock position near the chest wall unchanged compared to prior study. Apparently, this has been biopsied previously and was benign. No new lesions are identified. Recommend continued routine mammograms." The patient was without complaints, the breast exam was

benign, and she was asked to return in one year for follow-up and a bilateral mammogram.

In May 2013, four months before her next scheduled follow-up visit, the patient called the surgical group and indicated the mass had gotten larger and she wanted it examined. She was seen by a different general surgeon in the group, who examined her and noted a mass in the left breast at about 10 o'clock that was very large and fixated in both directions. It was classified as a BI-RADS IV on mammogram and ultrasound. The surgeon felt an excisional biopsy was warranted, and he explained the complications and risks to the patient.

In June 2013, the surgeon performed a left modified radical mastectomy and a right simple mastectomy, with reconstruction by plastic surgery. The patient was given a diagnosis of stage IIIc adenocarcinoma of the breast. Chemotherapy was initiated within two months by an oncologist and the patient also underwent radiation treatment.

The patient's quality of life on chemo and radiation therapies was quite poor and she suffered from many complications, including a recurrence two months after the mastectomy, joint pain, fatigue, change in sleep patterns, vision changes, memory issues, numbness and tingling of her feet, skin rash on her arms, loss of appetite, and daily diarrhea, as well as occasional palpitations,



shortness of breath, frequent urination, and hot flashes. A March 2017 CT/PET scan showed no active breast cancer. CT/PET scans and bone scans are performed every six months, and the patient remains with fatigue, neuropathy, and joint pain.

Lawsuit Filed and Expert Reviews

A lawsuit was filed by the patient against the MLMIC-insured general surgeon who provided the initial treatment, as well as against her surgical group practice.

Expert reviews in various specialties were extremely critical of the care provided by the initial general

surgeon. Two general surgeons who reviewed the case indicated that a biopsy/MRI should have been performed following the ultrasound of March 2012, given the plaintiff's extremely high risk for disease and the ultrasound result recommending a repeat biopsy. They questioned why the general surgeon performed the breast biopsy herself, believing such procedures were best left to radiologists with specialized training.

The strong family history of breast cancer, dense breast tissue, irregular mass with rough edges, and calcifications all should have signaled to the general surgeon that the pathology of

They questioned why the general surgeon performed the breast biopsy herself, believing such procedures were best left to radiologists with specialized training.

fibroadenoma (known to be present and around cancer) was wrong and an excision or biopsy of the calcifications should have been done. Either way, the patient had required close monitoring.

An oncology reviewer felt the general surgeon should not have done the biopsy herself in August 2011, and there should have been at least three core biopsies taken instead of one. This oncologist also opined that the surgeon should have followed the radiologist's recommendation in March 2012 for a repeat biopsy. Follow-up imaging was necessary to make sure no recurring mass was present. As a diagnosis of stage IIIC has a very poor prognosis, he opined that her cancer was unlikely to be curable, and that the patient's chance for survival would have been close to 100% had her condition been diagnosed in 2011.

Finally, a radiology reviewer agreed that a biopsy with one core was inadequate, and the failure to re-biopsy after the sonogram in March 2012 was inexcusable.

Settlement

This case was settled out of court on behalf of the general surgeon and her former surgical group for a total of \$3 million. That amount was comprised of the general surgeon's \$1.3 million primary policy, her \$1 million excess policy, and \$700,000 from the surgical group's professional entity policy.



In this case, the general surgeon was “anchored” to her diagnosis of fibrocystic breast disease.

A Legal and Risk Management Analysis

The main allegation against the defendants in this case was that the treating physician failed to diagnose the patient's breast cancer. Any failure to diagnose cancer not only requires the defense team and reviewers to look at whether the standard of care was met, but also whether an earlier diagnosis would have impacted the patient's staging and prognosis.

Any failure to diagnose cancer not only requires the defense team and reviewers to look at whether the standard of care was met, but also whether an earlier diagnosis would have impacted the patient's staging and prognosis.

Multiple experts agreed that there were significant concerns with the care provided by the general surgeon, and that an earlier diagnosis would have resulted in a better chance of survival for the patient. The surgeon also failed to consider that the patient's family history was significant for breast cancer in her mother and both grandmothers. Therefore, the care of the general surgeon could not be defended.

Ultimately, the general surgeon's failure to perform an adequate, three-core biopsy, coupled with her failure to perform a second biopsy as suggested by the radiologist, resulted in the late diagnosis of the patient's breast cancer.

But why did the general surgeon fail to perform the second biopsy?

In this case, the general surgeon was “anchored” to her diagnosis of fibrocystic breast disease. Anchoring is a form of cognitive bias that occurs when a medical provider has a narrow focus on a single feature in a patient's presentation to support a diagnostic hypothesis, even if other concurrent features or subsequent information refutes this hypothesis.

The patient in this case had imaging performed that should have raised suspicion for a malignancy, but no further investigation was done. Rather, the general surgeon focused on the previous pathology reports of benign fibrous tissue. Relying on her convictions as to the diagnosis, and contrary to the changes noted on the subsequent mammogram and sonogram, as well as the recommendations from the radiologist, the general surgeon never performed an additional biopsy.

Interestingly, the biopsy results that the general surgeon was anchored to were from the single core biopsy. At this time, as the findings on imaging and pathology were discordant, the general surgeon should have considered that the biopsy may not have been adequate. As noted by the experts, a single core biopsy is not the standard of care.

As noted by the experts, a single core biopsy is not the standard of care.


While the general surgeon did encounter bleeding during the initial biopsy, once additional imaging raised concerns, she should have given those changes consideration and included the possibility for malignancy in

her diagnosis. Had the general surgeon performed a proper biopsy, investigated the changes in the patient’s imaging findings, and followed the radiologist’s recommendations instead of being anchored to her initial diagnosis, the care of the surgeon could have been defensible and would not have resulted in a stage III cancer diagnosis.

This case illustrates the severity of outcomes that may occur in the face of the cognitive bias of anchoring to a diagnosis and a plan of care. It also settled for such a large amount because the patient was a young working mother of two children and suffered a difficult course of treatment with complications and a poor prognosis.



Danielle Mikalajunas Fogel is an attorney at Fager Amsler Keller & Schoppmann, LLP, counsel to MLMIC Insurance Company.
dfogel@fakslaw.com



Edward Krause is an Assistant Vice President of Claims for MLMIC Insurance Company.
ekrause@mlmic.com

Stay Connected

Get the latest updates and industry news from New York’s #1 medical professional liability insurer. No one knows New York better than MLMIC.



Follow us for important industry updates and risk management resources.

linkedin.com/company/mlmic



Get headlines and alerts that impact patient care in New York.

twitter.com/mlmic



Stay current with MLMIC’s Healthcare Weekly newsletter. Sign up at:

MLMIC.com/healthcare-weekly



MLMIC Stands with You During the COVID-19 Pandemic

As MLMIC Insurance Company's premiere issue of *The Scope* goes to press, New York State is still in the midst of the COVID-19 pandemic. We at MLMIC are and will always be grateful for the actions of the extraordinary, dedicated and courageous medical professionals who have led the way through this crisis.

Society as a whole has been affected by this novel coronavirus, but the medical community is one of the most affected groups. The way physicians practice medicine changed overnight, going from seeing patients in a traditional office setting to now seeing them via computer screens a la telemedicine, or primarily speaking with patients via telephone. This is a major adjustment for both the physician and the patient. MLMIC is making daily efforts to make this adjustment as professional, efficient, and comfortable as possible for its policyholders.

MLMIC is making daily efforts to make this adjustment as professional, efficient, and comfortable as possible for its policyholders.

To support our community, MLMIC has sent email updates to policyholders, contracted producers, preferred savings program partners, and endorsed partners to provide updated information on relevant topics including:

- **Pre-recorded Webinars** on topics such as the legal and risk management aspects of practicing telemedicine in New York, and ongoing COVID-19 updates for healthcare providers.
- **COVID-19 Scam Alert** - serving as a reminder to all policyholders to contact MLMIC if they are uncertain as to any offerings, emails involving professional liability coverage, and before purchasing unsolicited insurance policies or changing the terms of current insurance policies.
- **COVID-19 Business Disruption and Financial Hardship** - providing information regarding the updated premium installment due date and our response to potential policy cancellations due to nonpayment of premium, as well as how payment due dates can be adjusted if a policyholder encounters a demonstrated financial hardship due to COVID-19.

We have also made this content available on our website. In addition to the distribution of emails, [MLMIC.com](https://www.mlmic.com) also provides a range of updated information relevant to the COVID-19 crisis, including:

- **Direct Support** measures for legal, policy and coverage issues, and claims-related matters.
- **Post-COVID-19 Preparation Strategies** that include downloadable versions of the MLMIC checklists for reopening for physician practices, hospitals, and ambulatory surgery centers, as well as the AMA Guidelines for Reopening.
- **Informational Resources** comprised of a vast array of published articles on legal, medical and operational topics, as well as webinars on telehealth and COVID-19 updates.
- **Executive Orders** issued by Governor Andrew Cuomo.
- **Frequently Asked Questions** regarding treatment, practicing medicine during the pandemic, policy coverage, and liability matters.
- **MLMIC Blog Posts** relevant to the COVID-19 crisis.

For the latest information on developing issues relative to COVID-19, MLMIC encourages you to visit [MLMIC.com](https://www.mlmic.com). You can also follow MLMIC on Twitter and LinkedIn, and updates are available on the MLMIC.com blog.

COVID-19 may have changed both professional and personal ways of life for now, but we look forward to better days ahead. We missed seeing so many of you at the MSSNY House of Delegates Risk Management Seminar in April, as well as at other events around the state that had to be postponed. We greatly anticipate the day when we can safely gather again.

We at MLMIC hope that our endeavors have provided support and assistance to you in some way during this unprecedented and challenging time. Thank you for your dedication and service to all New Yorkers.

The MLMIC Insurance Company Family

DIRECT SUPPORT

MLMIC is here to support the thousands of New York physicians, nurses, dentists, allied professionals, facilities, and dedicated healthcare teams engaging the coronavirus COVID-19 on the front line.

MLMIC's toll-free 24/7 Legal Hotline

Call **(855) FAKS-LAW**
(855-325-7529)

Claims, risk management, coverage and policies questions?

Call **(800) ASK-MLMIC**
(800-275-6564) and every effort will be made to handle inquiries on an immediate basis. MLMIC can also be contacted by email via the MLMIC website: [MLMIC.com](https://www.mlmic.com).

Post-COVID-19 Preparation Strategies

Review checklists with guidance and important actions to keep in mind at [MLMIC.com/covid-19](https://www.mlmic.com/covid-19).



New York City

Two Park Avenue
New York, New York 10016
(212) 576-9800
(800) 275-6564

Latham

8 British American Boulevard
Latham, New York 12110
(518) 786-2700
(800) 635-0666

Long Island

90 Merrick Avenue
East Meadow, New York 11554
(516) 794-7200
(877) 777-3560

Syracuse

2 Clinton Square
Syracuse, New York 13202
(315) 428-1188
(800) 356-4056

Buffalo

300 International Drive
Suite 100
Williamsville, New York 14221